



## CASUISTIC PAPER

Wojciech Kołodziej<sup>1,3(ABCG)</sup>, Gabriela Kołodziej-Lackorzyńska<sup>2,3(DEFG)</sup>,  
Dawid Bodusz<sup>1(CD)</sup>, Krzysztof Kołodziej<sup>2,3(DEG)</sup>

# Embolization as a method of treating aneurysms intracranial – a case study

<sup>1</sup> Faculty of Administration and Management in Rzeszow, Humanitas University in Sosnowiec, Poland

<sup>2</sup> Institute of Health Science, Medical College of Rzeszow University, Rzeszow, Poland

<sup>3</sup> St. Queen Jadwiga Clinical District Hospital, No 2, Rzeszow, Poland

## ABSTRACT

**Introduction.** Cerebrovascular accidents are the third leading cause of death in developed countries. It is a very debilitating disease of the brain structures in which aneurysms are located. For a long time, the only method of treating intracranial aneurysms was surgery. However, mainly due to the difficult placement of the aneurysms, surgical treatment was very difficult. Therefore, in 1953, the method of percutaneous arterial catheterization was developed, which became the basis for the improvement of the field of interventional radiology.

**Aim.** The aim of the research is to describe the method of embolization of intracranial aneurysms and to illustrate it in selected clinical cases.

**Description of the case.** Surgical management of a 60-year-old woman with intracranial aneurysm of the anterior communicating artery after performing computed tomography with contrast.

**Conclusion.** The method of embolization of intracranial aneurysms is a reliable and accurate surgical method that significantly improves the health condition, quality of life of patients and reduces the mortality rate of cerebrovascular events.

**Keywords.** embolization, intracranial aneurysms, neurosurgical procedures in the treatment of aneurysms

## Introduction

Intracranial aneurysm is one of the most common diseases of the neurovascular system. They are called weakened vasodilations and belong to the group of cerebrovascular accidents. They are the third leading cause of death in developed countries. Intracranial aneurysms is the disease that significantly destroys the structures

of the brain in which it is located. Cerebrovascular accidents have a complex but not fully understood etiology.<sup>1</sup> Researchers from the University of Portugal have shown that intracranial aneurysms are the most common type of malignant tumors observed at the clinical stage due to a specific mechanism of its development and occurrence.<sup>2</sup>

**Corresponding author:** Gabriela Kołodziej-Lackorzyńska, e-mail: [gabriela.kolodziej92@gmail.com](mailto:gabriela.kolodziej92@gmail.com)

**Participation of co-authors:** A – Author of the concept and objectives of paper; B – collection of data; C – implementation of research; D – elaborate, analysis and interpretation of data; E – statistical analysis; F – preparation of a manuscript; G – working out the literature; H – obtaining funds

Received: 13.05.2021 | Accepted: 28.05.2021

Publication date: September 2021

Kołodziej W, Kołodziej-Lackorzyńska G, Bodusz D, Kołodziej K. *Embolization as a method of treating aneurysms intracranial – case study.* *Eur J Clin Exp Med.* 2021;19(3):262–266. doi: 10.15584/ejcem.2021.3.10.



The aneurysm ruptures in more than 50% of cases, which results in spontaneous subarachnoid haemorrhage (SAH) in approximately 80% of patients.<sup>3</sup> The most catastrophic consequence of aneurysm rupture is 50% mortality and in 30-50% of cases the cause of severe neurological complications resulting in significant disability in survivors.<sup>4</sup>

There are numerous scientific reports in foreign literature that describe the pathogenesis of aneurysms. These cerebrovascular events happen as a result of arterial dilatation due to acquired or congenital lesions leading to a decrease in the mechanical resistance of the artery walls. Most often it is a type of damage to the structure of the vessel wall with a characteristic lack or weakening of the muscular and/or elastic membrane, which may cause the inner membrane to bulge outside the vessel.<sup>5-7</sup> In the last few decades, surgery has been the only treatment for intracranial aneurysms. However, the neurosurgical treatment was very limited by the difficult location of the aneurysms, making surgery impossible. Hence, in 1953, the method of percutaneous arterial catheterization was described by the Swedish radiologist Sven Seldinger, which became the foundation for the development of a new field – interventional radiology.<sup>8-10</sup>

The embolization procedure consists in placing platinum, detachable embolization coils in the aneurysm sac in order to fill it as much as possible, so that the aneurysm is excluded from the cerebral circulation. The spirals are placed through a microcatheter, the end of which is in the aneurysm sac. Most often, the procedure is performed through access from the common femoral artery. In rare situations, e.g. in the case of obstruction of both common iliac arteries, it can be performed through the brachial artery or directly through the common carotid artery.

Currently, it is found that the embolization method can disable as much as 80% of all existing aneurysms by placing embolization materials into the vessel lumen using a microcatheter. Patients' quality of life has improved since intracranial embolization began, and the mortality rate associated with such cerebrovascular incidents has significantly decreased.

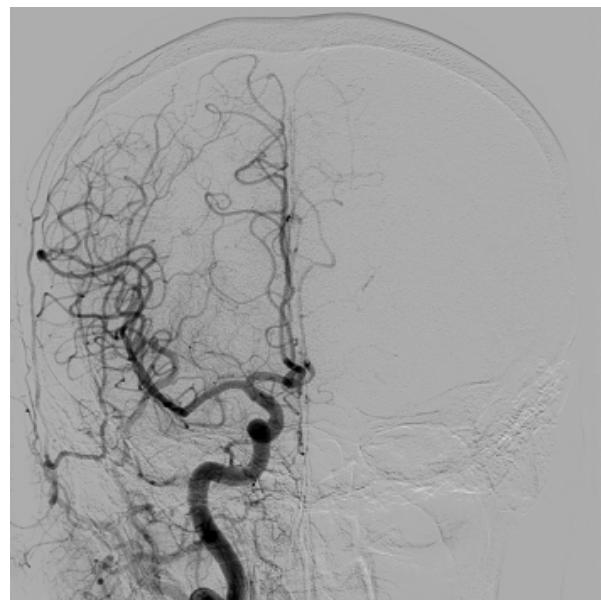
### Aim

The aim of this study is to describe the method of embolization of intracranial aneurysms and to illustrate it in a selected clinical case, treated at the St. Queen Jadwiga Clinical District Hospital, No 2 in Rzeszow. In order to explore the topic, scientific articles, medical books and databases were analyzed in detail, i.e. PubMed, ScienceDirect, Google Scholar, EBSCO and Free Medical Journals.

### Description of the case

A 60-year-old patient came to the Hospital Emergency Department (HED), claiming that the cause of her health

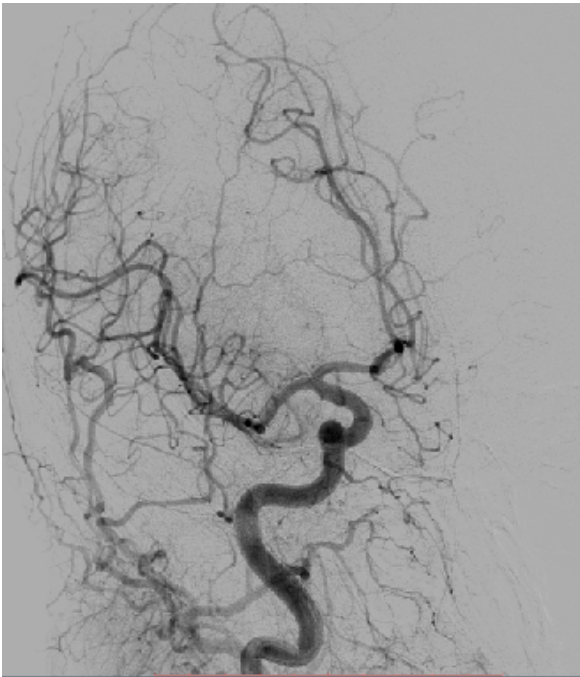
was a two-day constant headache, nausea, general malaise and vision problems. Neurological symptoms were not found. The patient reported a possible fall at home as the cause of the headache. The doctor on duty referred the patient to a computed tomography with contrast, which showed the aneurysm on the anterior communicating artery. The woman was admitted to the Department of Neurosurgery, where a neurosurgeon qualified her for cerebral angiography. The examination was performed using the Seldinger method of puncture of the right common femoral artery. Both common carotid arteries and the left vertebral artery were catheterized. The right internal carotid artery was additionally examined by rotational angiography and spatial reconstructions were performed. Visipaque non-ionic contrast agent was given. In the area of the anterior communicating artery, a sac-like aneurysm with dimensions of 4.5x3x2.7 mm, filled from the right side, was visible. Some traces of contrast agent from the left side were also found. The aneurysm is directed upwards and to the left side, the neck of the aneurysm is 2.1x1.7 mm. Funnel-shaped exit of the right posterior connecting artery. Hypoplastic P1 segment of the left posterior artery of the left brain, with visible supply of the posterior brain artery through the posterior connecting arteries (carotization). The examination showed the correct image of the main arterial trunks and their branches of deep veins and superficial brain and dural sinuses. Other cerebral vascular malformations were not visualized. The above description is illustrated in figures 1, 2, 3.



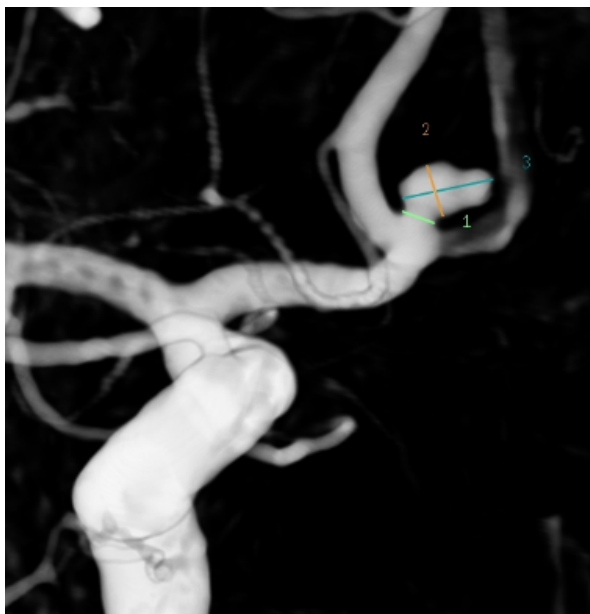**Fig. 1.** Cerebral angiography in the AP projection (the arrow in the figure shows the aneurysms of the anterior communicating artery, own source)

### Description of the aneurysm embolization procedure

The patient received general anesthesia. From the puncture of the right common femoral artery, the right in-

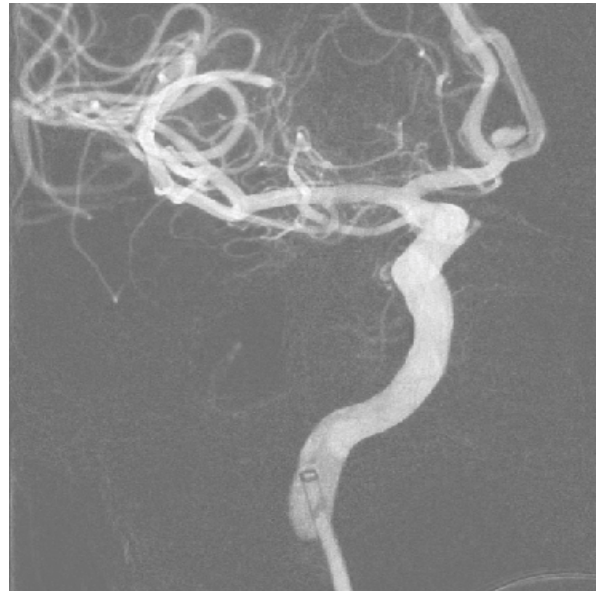


**Fig. 2.** Cerebral angiography in oblique projection (the arrow in the figure shows the aneurysms of the anterior communicating artery, own source)

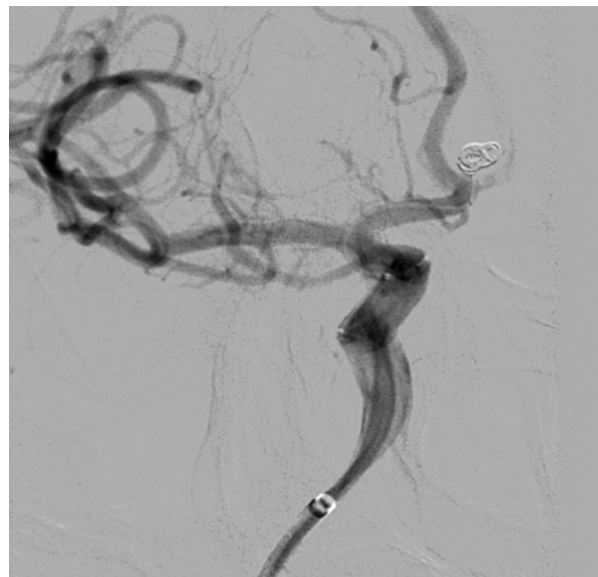

**Fig. 3.** Cerebral angiography study in 3D reconstruction (dimensions described above, own source)

ternal carotid artery was catheterized by the Seldinger method and angiography was performed which showed a sac-like aneurysm on the anterior communicating artery. Two embolization coils were inserted into the aneurysm sac using a microcatheter. Control angiographs showed complete closure of the aneurysm, and the surrounding vessels had patency. The course of the procedure without complications. The puncture site of the right common femoral artery was closed with the Angio-



**Fig. 4.** Beginning of the procedure of the anterior communicating artery aneurysm (own source)

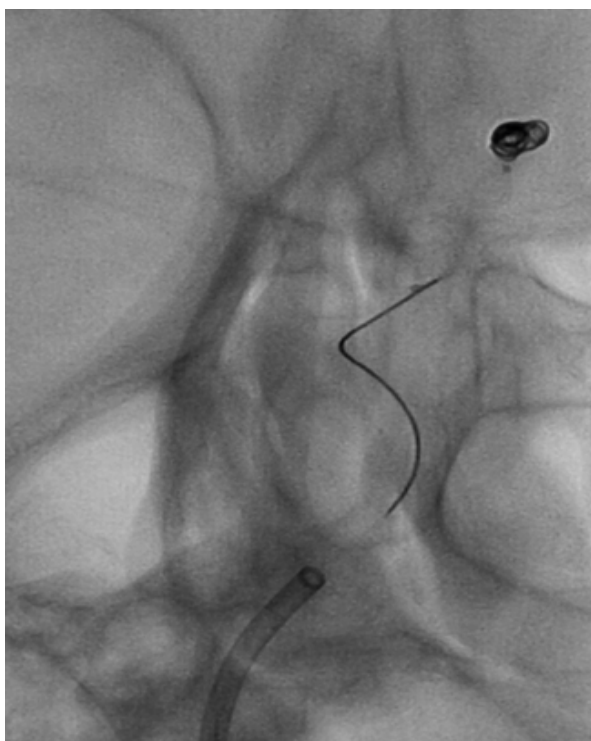


**Fig. 5.** Procedure of the anterior communicating artery aneurysm (own source)

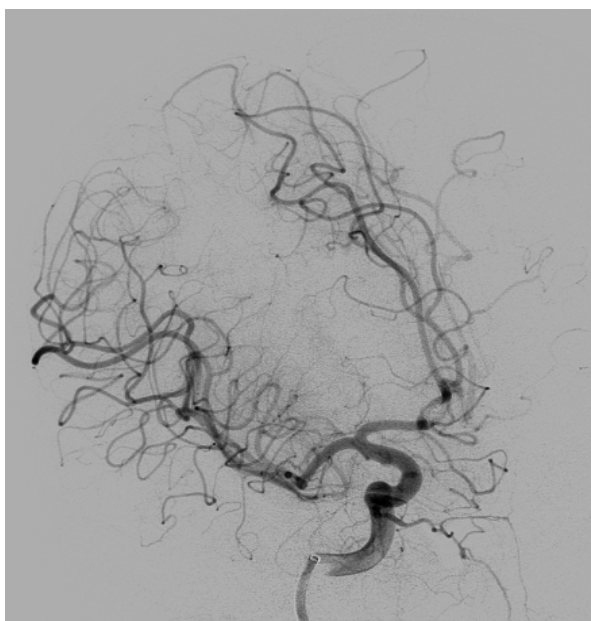
Seal system. The material from which the embolization coils were made is not a contraindication to placing the patient in the magnetic field during the magnetic resonance imaging (Fig. 4-7).

## Discussion

Cerebrovascular accidents are the third leading cause of death in developed countries. This group of cerebrovascular incidents includes, inter alia, intracranial aneurysms, i.e. pathological dilatation of cerebral vessels occurring at bifurcations of intracranial arteries. It is a very debilitating disease of the brain structures in which aneurysms are located. It is estimated that intra-



**Fig. 6.** Procedure of the anterior communicating artery aneurysm (no contrast, own source)



**Fig. 7.** The end of the aneurysm embolization procedure (own source)

cranial aneurysms occur in 6% of the world's population, of which 2% develop aneurysm rupture due to the incidence of subarachnoid haemorrhage.<sup>11</sup> Non-ruptured intracranial aneurysms can be diagnosed accidentally by imaging the skull to detect damage/injuries or other pathologies, or by targeted high-risk screening, i.e. : in people with a family history of intracranial aneurysms.<sup>12</sup> The most destructive consequence of an

intracranial aneurysm rupture is subarachnoid haemorrhage, which may be mildly symptomatic or lead to severe disability or even death. It is estimated that the mortality associated with subarachnoid haemorrhage affects approximately  $\frac{1}{3}$  to  $\frac{1}{2}$  of all patients.<sup>12-13</sup> However, despite its prevalence and impact on the body, the etiopathogenesis of intracranial aneurysms is still unknown.<sup>14</sup> In 85% of patients, intracranial aneurysms are located on the anterior part of the Willis arterial circle, the most of which, i.e. 35%, can be located on the anterior connecting artery.<sup>15</sup> According to the scientific research conducted by Juvel, it can be concluded that the risk of bleeding aneurysm located in front of the arterial circle of the brain ranges from 1.6-1.9% per year.<sup>16</sup>

In the case described above, the physical examination revealed the following symptoms: 2-day severe headache, nausea, general malaise and vision problems. The symptoms described by the patient probably appeared after the fall at home. The symptoms mentioned by the patient may indicate many injuries within the brain and head, hence the doctor on duty referred the patient for further imaging tests. Computed tomography of the head was performed with contrast, which showed an aneurysm of the anterior connecting artery. After the medical history and physical examination, the patient was admitted to the Department of Neurosurgery, where a neurosurgeon qualified her for cerebral (diagnostic) angiography.

The decision to choose the embolization treatment of intracranial aneurysms was made immediately after the diagnostic angiography was performed. In the studies by Petridis et al., the symptoms of the patient of the Provincial Clinical Hospital No. 2 named after St. Jadwiga Queen in Rzeszow are characteristic symptoms of intracranial aneurysm.<sup>17</sup> Computed tomography is a very sensitive examination (about 95%) and can reveal deficits within the examined area.<sup>17</sup> Computed tomography with contrast ensures the visualization of the cerebral vessel in three dimensions, which enables a precise assessment of vascular brain and the base of the skull bone, making it much easier to plan the surgical procedure.<sup>18</sup>

After the surgery, the patient was carefully looked after and monitored. As indicated, the patient was given prophylactic cerebral-protective, analgesic, antibacterial and sedative agents. At the discharge from the hospital, the patient was informed about the necessity to attend a follow-up visit, during which diagnostic angiography would be performed again to detect recurrence of the intracranial aneurysm. The test result was negative.

Intracranial aneurysms are now detected more frequently due to improved imaging techniques. After detecting a lesion, the natural history of the aneurysm should be compared with the risk of planned surgery, taking into account the size, morphology, location of the aneurysm, as well as the patient's age and comorbidities. The patient's history and physical examination should also be

very scrupulous.<sup>1</sup> The endovascular embolization treatment of aneurysms has become an acceptable treatment with good clinical outcomes and provides adequate protection against re-bleeding and rupture of aneurysms.<sup>19</sup>

Intracranial aneurysms are among the most common cerebrovascular defects. These defects are the third leading cause of death in the world in developed countries. By definition, intracranial aneurysms are cerebrovascular events arising from the weakening of blood vessels within the damaged area. The disease significantly destroys the brain structures in which aneurysms are located, contributing to long-term disability or death. The etiology of cerebrovascular defects is still not fully understood.

In recent decades, the only method of treating intracranial aneurysms has been surgery, but due to the limited possibilities of imaging tests and the difficult location of cerebrovascular lesions, treatment has been significantly limited or even impossible. Hence, in the 1950s, the method of percutaneous arterial catheterization – the Seldinger method – was described and presented. The innovative technique has become the basis for the development of interventional radiology. Thanks to the Swedish radiologist (Sven Seldinger), the diagnosis of intracranial artery aneurysms has increased significantly, which resulted in an increase in the number of procedures performed and the recognition of cerebrovascular incidents has increased.

Currently, it is determined that the embolization method can disable up to 80% of all existing aneurysms by placing embolization materials into the vessel lumen using a microcatheter.

Since intracranial embolization procedures have begun, patients' quality of life has improved, the mortality rate has decreased, and the level of disability associated with such cerebrovascular events has decreased.

## Conclusion

As a result of the analysis of the literature and own research, the following conclusion was drawn, i.e. treatment of intracranial artery aneurysms using the embolization method – the Seldinger method is a fundamental treatment that results in positive effects, and additionally reduces the level of disability and death caused by cerebrovascular defects.

## References

1. Yon KI, Shang HS, Seung KB. Complications of endovascular treatment for intracranial aneurysms: Management and prevention. *Interv Neuroradiol.* 2018;24(3):237-245.
2. Campodeaño L, Oliveira MSN., Pinho FT. A review of computational hemodynamics in middle cerebral aneurysms and rheological models for blood flow. *Appl Mech Rev.* 2015;67(3):030801.
3. Amenta PS, Dalyai RT, Kung D, et al. Stent-assisted coiling of wide-necked aneurysms in the setting of acute subarachnoid hemorrhage: experience in 65 patients. *Neurosurgery.* 2012;70(6):1415-1429.
4. Texakalidis P, Sweid A, Mouchtouris N, et al. Aneurysm Formation, Growth, and Rupture: The Biology and Physics of Cerebral Aneurysms. *World Neurosurg.* 2019;130:277-284.
5. Avery RK, Albadawi H, Akbari M, et al. An injectable shear-thinning biomaterial for endovascular embolization. *Sci Transl Med.* 2016;16;8(365):365ra156.
6. Calero A, Illig KA. Overview of aortic aneurysm management in the endovascular era. *Semin Vasc Surg.* 2016;29(1-2):3-17.
7. Mocco J, Brown RD, Torner JC, et al. International Study of Unruptured Intracranial Aneurysms Investigators. Aneurysm Morphology and Prediction of Rupture: An International Study of Unruptured Intracranial Aneurysms Analysis. *Neurosurgery.* 2018;1;82(4):491-496.
8. Vivancos J, Gilo F, Frutos R, et al. Clinical management guidelines for subarachnoid haemorrhage. Diagnosis and treatment. *Neurologia.* 2014;29(6):353-370.
9. Gabriel J, Rinkel E. Management of patients with aneurysmal subarachnoid haemorrhage. *Curr Opin Neurol.* 2016;29(1):37-41.
10. Gralak-Łachowska D, Lewandowski P. Dostępny naczyniowe w kardiologii inwazyjnej. *Postępy Nauk Medycznych* 2015;28(11B):74-78.
11. Rinkel GJ, Djibuti M, Algra A, van Gijn J. Prevalence and risk of rupture of intracranial aneurysms: a systematic review. *Stroke.* 1998;29:251-256.
12. Nieuwkamp DJ, Setz LE, Algra , et al. Changes in case fatality of aneurysmal subarachnoid haemorrhage over time, according to age, sex, and region: a meta-analysis. *Lancet Neurol.* 2009;8:635-642.
13. Greving JP, Wermer MJ, Brown RD, et al. Development of the PHASES score for prediction of risk of rupture of intracranial aneurysms: a pooled analysis of six prospective cohort studies. *Lancet Neurol.* 2014;13:59-66.
14. Vlak MH, Algra A, Brandenburg, et al. Prevalence of unruptured intracranial aneurysms, with emphasis on sex, age, comorbidity, country, and time period: a systematic review and meta-analysis. *Lancet Neurol.* 2011;10:626-636.
15. Ząbek M. *Krwawienie podpajęczynówkowe. W: Zarys neurochirurgii.* Red. Ząbek M. Warszawa: PZWL; 1999.
16. Juvela S. Growth and rupture of unruptured intracranial aneurysms. *J Neurosurgery* 2019;131:843-851.
17. Petridis AK , Kamp MA, Cornelius JF, et al. Aneurysmal Subarachnoid Hemorrhage. *Dtsch Arztebl Int.* 2017;31;114(13):226-236.
18. Ajiboye N, Chalouhi N, Starke MR i wsp. Unruptured Cerebral Aneurysms: Evaluation and Management. *Scientific World Journal.* 2015;2015:954954.
19. Wan J, Gu W, Zhang X, et al. Endovascular coil embolization of aneurysm neck for the treatment of ruptured intracranial aneurysm with bleb formation. *Med Sci Monit.* 2014;20:1121-1128.